29icr2016
INTERNATIONAL CONGRESS OF RADIOLOGY
Buenos Aires, Argentina

WHAT LIES BEHIND THE EYE

OPTIC NERVE LESIONS

AUTHORS: VIEIRA FILHO, W. F.; BOLSI, G.; ROSSI, M.D.; TIBANA, L.T.; RIVERO, R.L.M.; MENDONÇA, R.A.

DASA

São Paulo - Brazil

Disclosures: None

THE OPTIC NERVE

A true brain extension rather than a nerve itself

It is because it is myelinated by oligodendrocytes rather than Schwann cells as well

The meninges surrounds it

THE OPTIC NERVE

It is commonly divided in four segments:

1. Intraocular

   1mm length
   Axons cells emerge from globe (lamina cribrosa) to nerve head

2. Intraorbital

   20 - 30 mm length
   From nerve head to optic canal
   Covered by 3 meningeal layers -Cerebral spinal fluid contiguous to then
   Central retinal artery and vein runs along from the mid- point to distal end
   Longer than the distance from chiasm to globe (allows eye movement)

THE OPTIC NERVE

It's commonly divided in four segments:

3. Intracanalicular

   4-10 mm length
   Intra bony optic canal
   Ophthalmic artery runs inferior to it

4. Intracranial (Cisternal)

   10 mm length
   From optic canal to optic chiasm
   Covered by pia only

ANATOMICS 101

Image from my.statdx.com

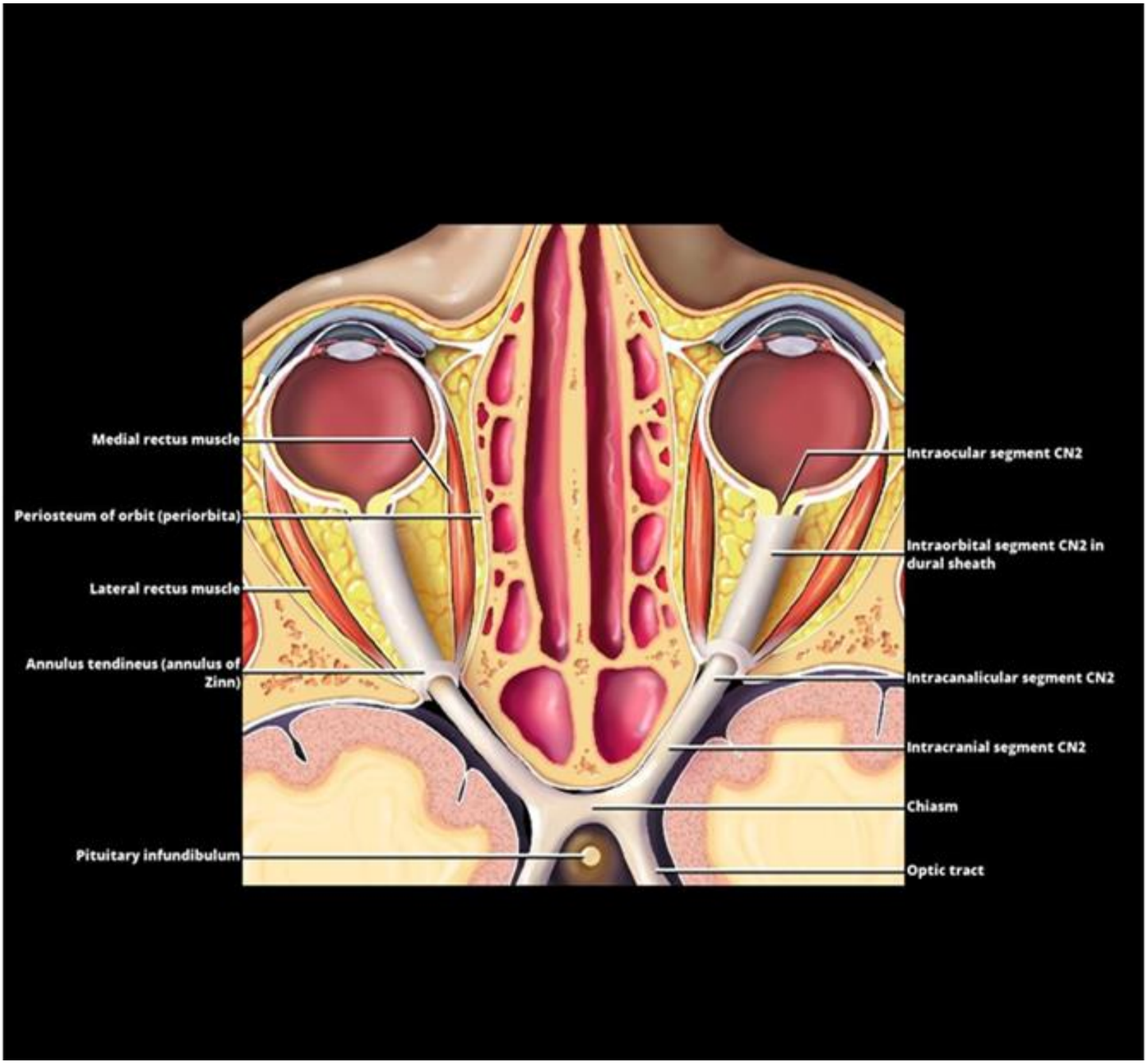

Axial graphic of orbit shows the 4 segments of optic nerve (intraocular, intraorbital, intracanalicular and intracranial). At annulus of Zinn dural sheath of intraorbital segment becomes contiguous with periorbita.

ANATOMICS 101

Image from my.statdx.com

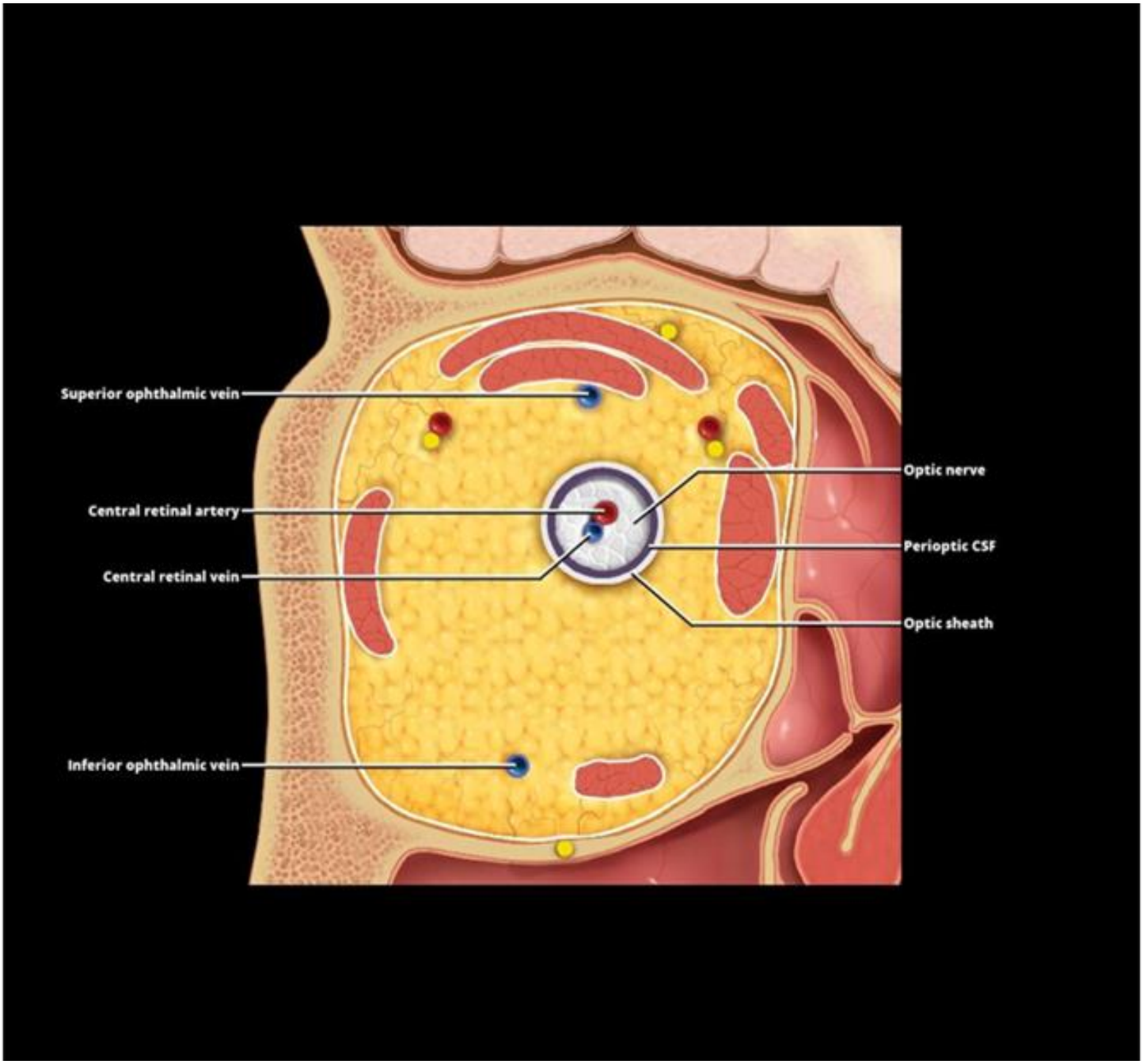

Optic nerve-sheath complex. The nerve is bathed by a thin layer of CSF which is contained by the dural optic sheath. The central retinal vessels are external to the optic sheath posteriorly in the orbit, and pierce the dura in the mid-portion of the nerve to travel within the substance of the nerve anteriorly.

IMAGING THE EYE

TC - best for evaluate osseous structures such as skull base and optic canal

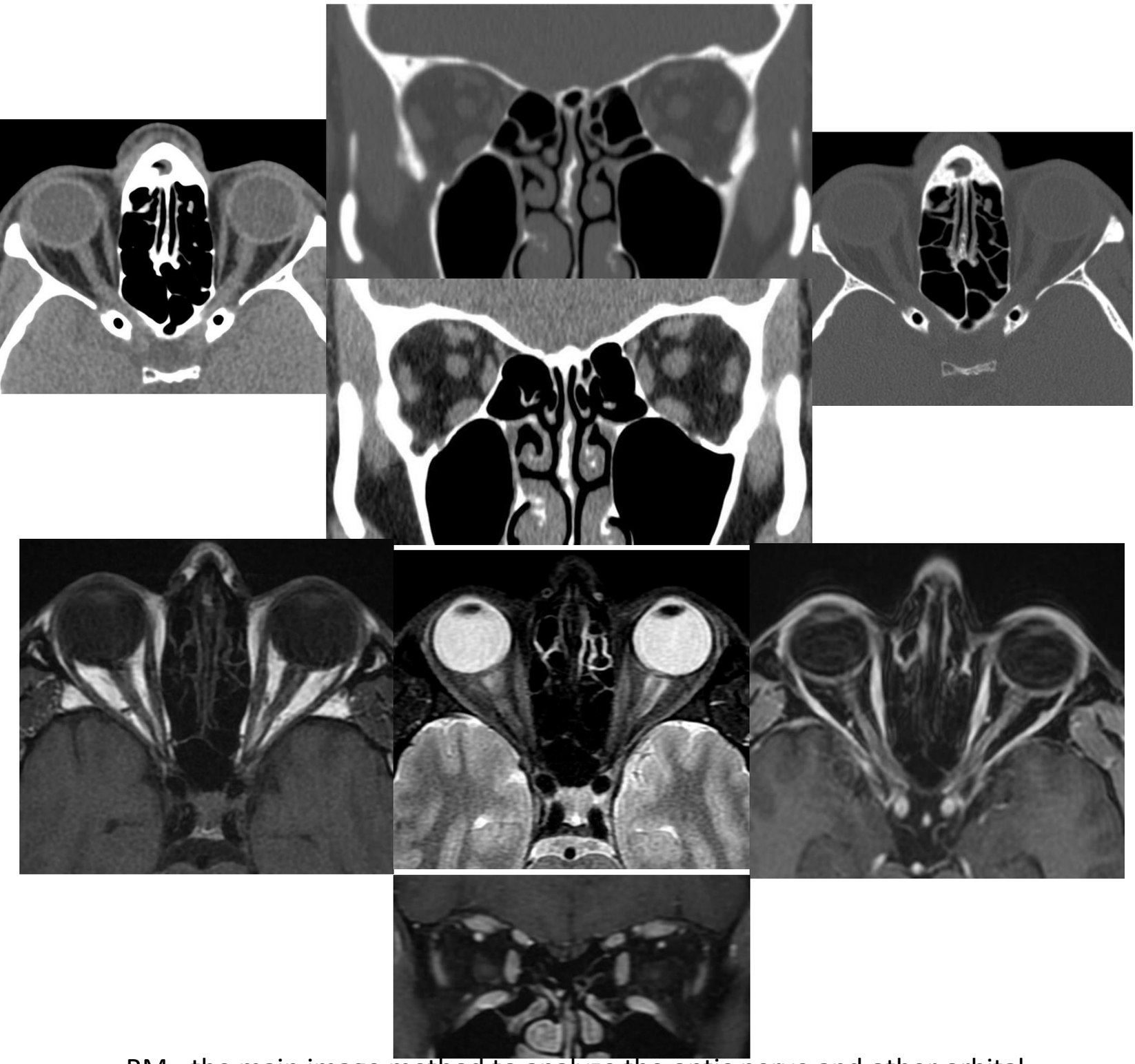

RM - the main image method to analyze the optic nerve and other orbital structures, except bones

GLIOMA

Pathology	Clinical findings
Pilocytic astrocytoma 66% of primary optic nerve tumours 4 times more common than meningiomas Children: more common 90% in 1º and 2º decades Female predominance Any nerve portion (inclusive chiasm) Adult: Rare / unilateral / think about malignancy	Benign, slow grow Uni or bilateral (remember NF1) Proptosis Acuity loss Low response to radiotherapy

GLIOMA

Neurofibromatosis type 1 and glioma

10-35% of patients with glioma have NF1

50% of patients with NF1 will develop glioma

* Look for other NF1 brain findings *

GLIOMA

MRI:
Diffuse and sinuous enlargement of the optic nerve
High T2 signal
Enhancement after contrast
Compression of adjacent orbital structures

DDX: meningioma, optic neuritis, metastasis, lymphoma.

Conservative treatment
Surgery reserved for accentuated proptosis, pain and progressive loss of sight.

(Optic glioma) Female, 6 years, ocular proptosis and decreased visual acuity on the right eye. MRI axial T2WI. Intraorbital and intracanalicular enlargement optic nerve on the right (arrows). Ectasia of the optic nerve sheath, as well as proptosis and deformity in the posterior wall of the eyeball in bottom figure. The left optic nerve is normal

MENINGIOMA

Pathology	Clinical findings
Second most prevailing optic nerve tumor Arising from optic nerve or sphenoid bone. Predilection for womens Around 30 to 40 years Rare in kids (Think about neurofibromatosis) - Not as common as glioma in these cases	Progressive loss of vision Proptosis No pain Conservative treatment with fractionated stereotactic radiotherapy

MENINGIOMA

MRI:
Diffuse optic sheath enlargement
Variable T2 sign
High enhancement with central preservation (tram track) , characteristic but not pathognomonic (can be found at idiopathic inflammatory orbital syndrome and optic neuritis).

CT:
Best for osseous changes (enlargement and sclerosis of the large sphenoid wing - high specificity)
Intralesional calcifications
High and homogeneous enhancement

(Meningioma of the optic nerve sheath) Female, 51, decreased visual acuity left. Asymmetrical involvement of the left optic nerve sheath by solid mass lesion hypointense on T2 , suffering intense enhancement by paramagnetic agent. Note that there are portions not involved the optic nerve sheath (arrows B and C figures) . In the coronal plane it is clear that most of the injury is the side portion of the sheath.

A. Post- contrast axial CT

B. axial MR T1

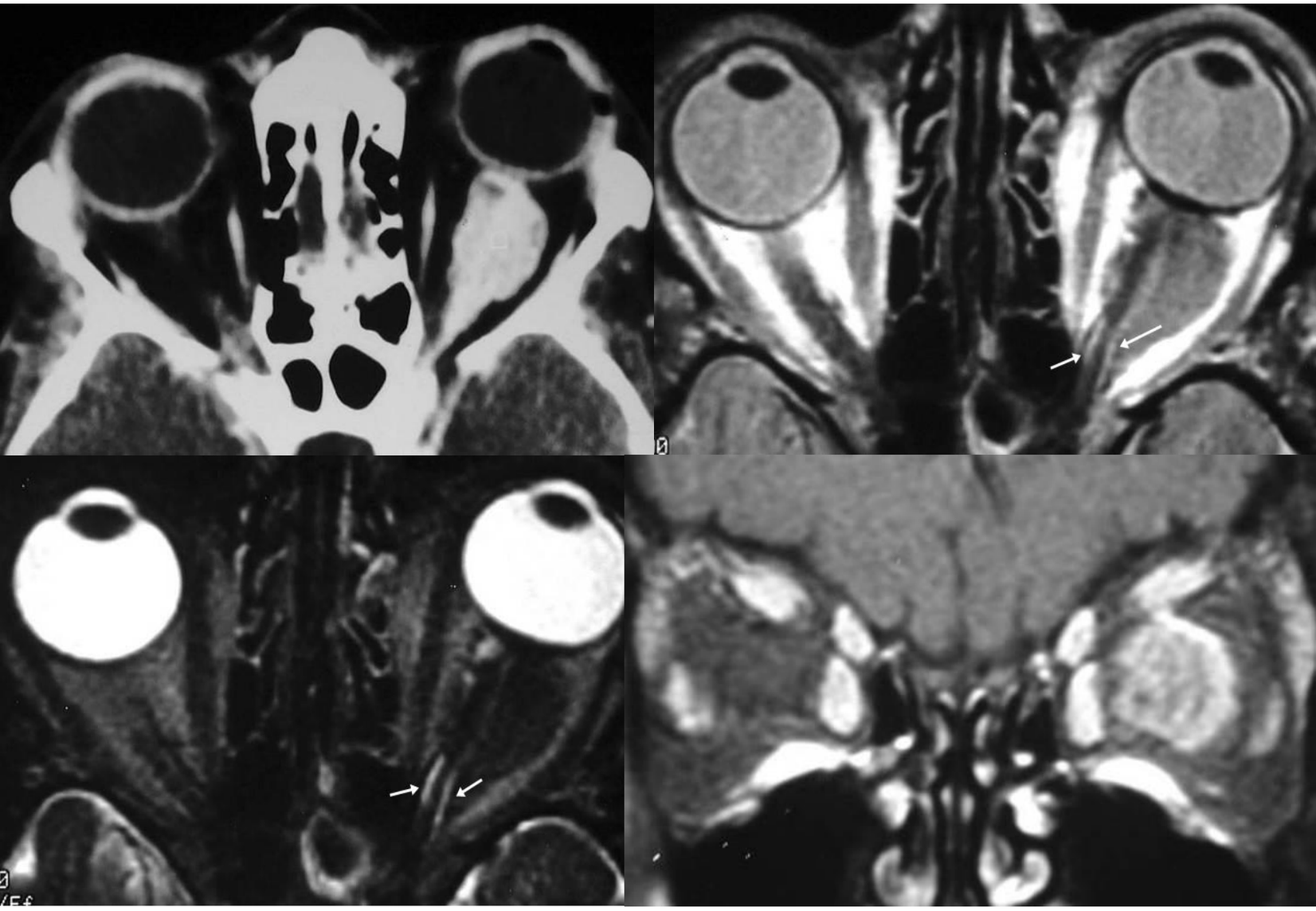

C. axial MR T2

D. Coronal MRI T1 gadolinium fat post- sat

OPTIC NEURITIS

Pathology	Clinical findings
Autoimmune process triggered by systemic disease, infection or any other factor 15-50 years Female predominance	Loss of sight Acute onset Pain Uni or bilateral Corticoids accelerates recovering of vision Look brain and spinal cord (Multiple sclerosis and optic neuromyelitis optica)

OPTIC NEURITIS

Causes: idiopathic, infectious, demyelinating, autoimmunes, radiation

MRI:
Nerve enlargement
High T2 signal
Postcontrast enhancement specially in intracanalicular and orbital (remember the anatomy? If not go back to the beginning)
Chronic phases - atrophy and T2 high signal

(Optic neuritis) Female , 20 years , episode of vision loss
Signal hyperintensity on T2 and enhancement throughout intra-orbital extension of the optic nerve

A. Axial T2 fat sat

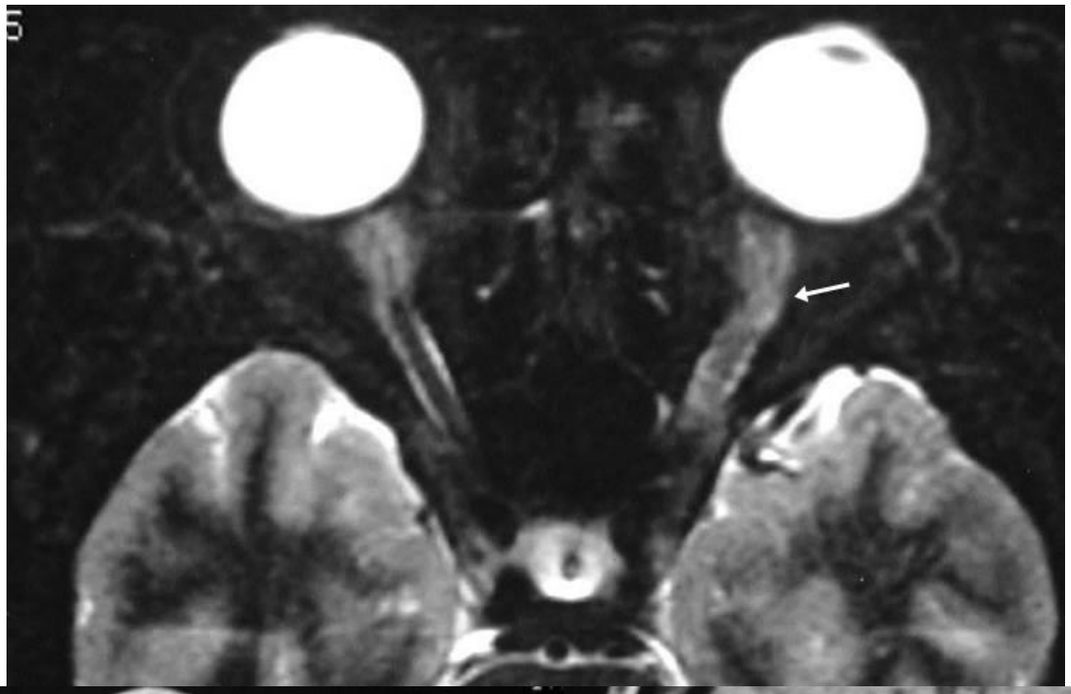

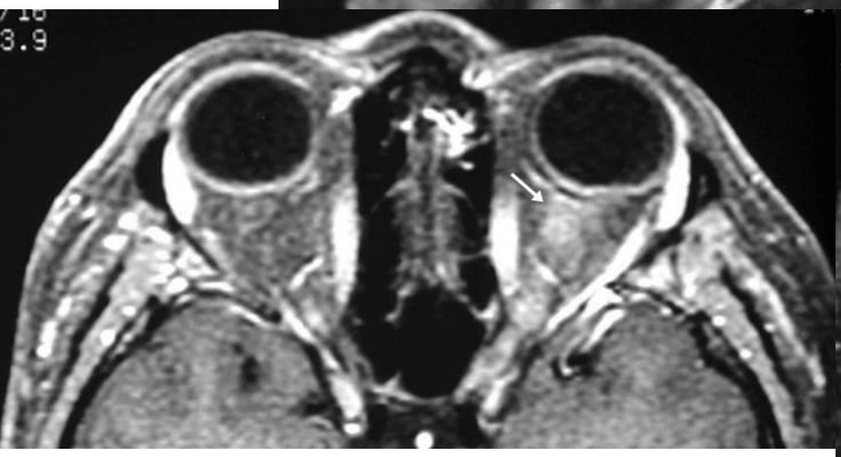

B. Axial post- gadolinium T1

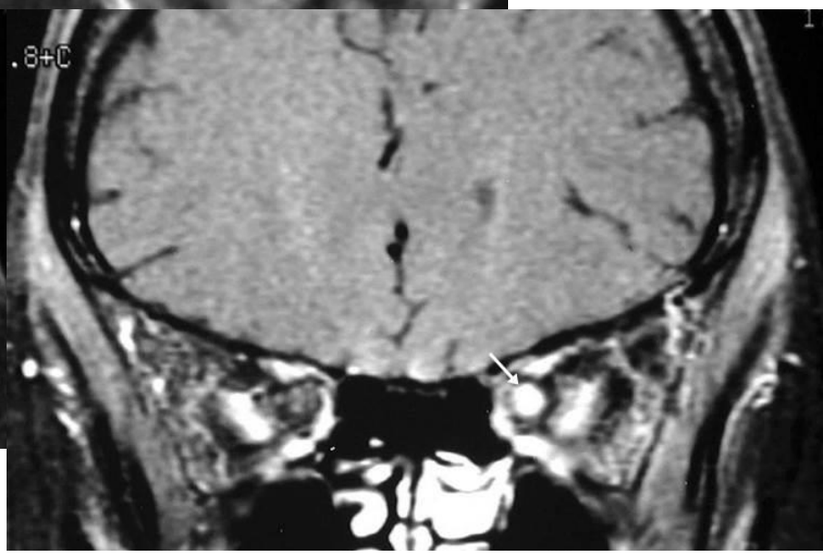

C. Coronal post- gadolinium T1

OPTIC NEURITIS

Multiple sclerosis:
Optic neuritis is the first manifestation in 15 - 30% of cases
50% of the optic neuritis cases evolve to multiple sclerosis in two to five years

Neuromyelitis optica:
Bilateral
Acute
Either expansile or atrophy
High T2 signal
Some may enhance
Transverse myelitis in cervical and thoracic spinal cord (extending for 3 or more vertebral levels)

(Optic neuritis) Male, 31 yo. Reduced visual acuity and pain in the left eye

T2WI hyperintensity of the left optic nerve, which presents blood brain barrier breakdown. In the brain one can observe plaques of demyelination in the deep and the subcortical white matter of the cerebral hemispheres and cerebellum

A. Coronal T2 fat sat

B. Coronal T1 fat sat post-gadolinium

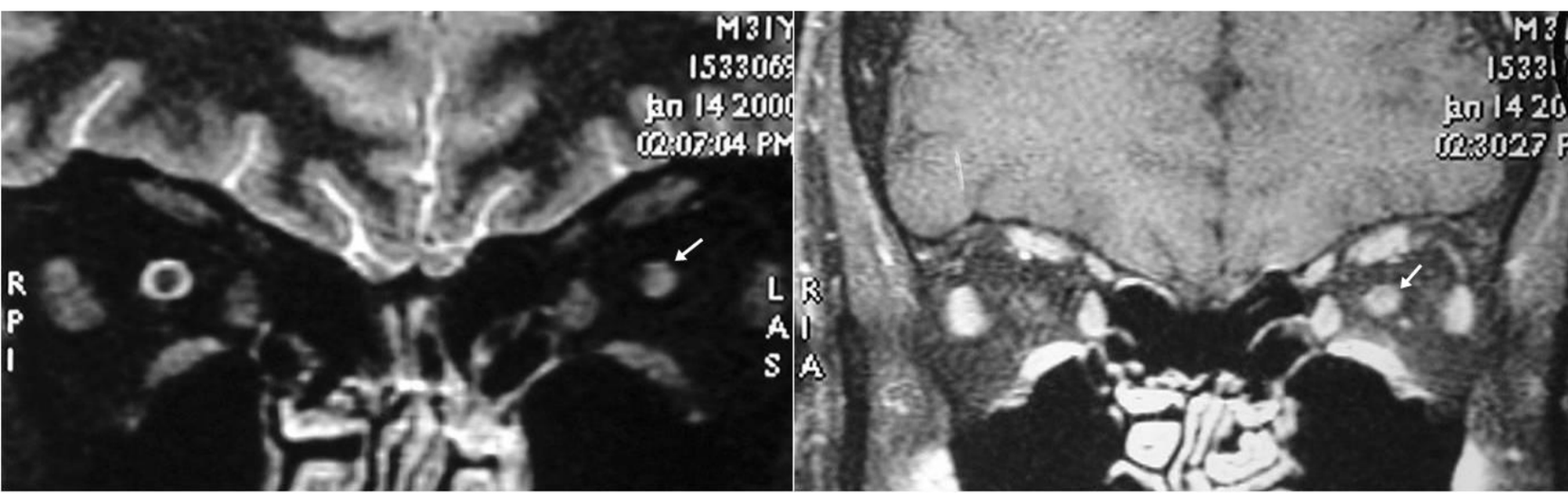

C and D.
FLAIR sagittal T2 brain

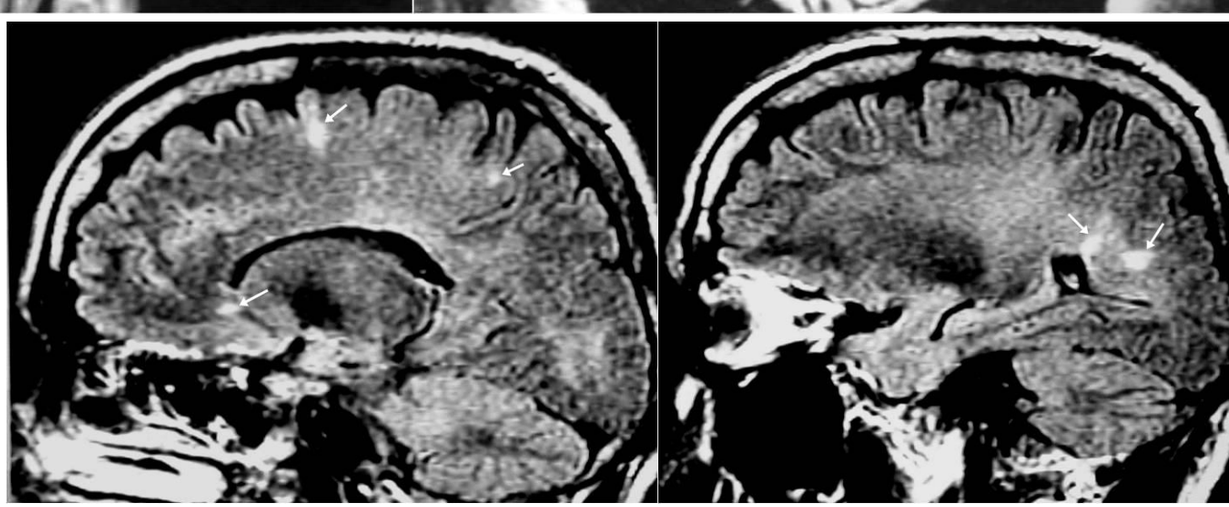

If you don´t remember to look for brain injuries, Dawson fingers will point to you!

IDIOPATHIC INFLAMMATORY ORBITAL SYNDROME

Pathology	Clinical findings
Third more common orbit affection	Acute/subacute onset
No local or systemic cause	Painful proptosis
Exclusion diagnosis	85% unilateral
Many times the diagnosis is only made by biopsy / histopathological findings	Erythema
Affects optic nerve on diffuse or perineural presentations	Blurred vision
No sex predilection	Quick response to corticoids

IDIOPATHIC INFLAMMATORY ORBITAL SYNDROME

IMAGING:
Focal or diffuse expansile lesion
Unilateral, rarely bilateral
Three compartments (pre-septal, extraconal and intraconal)
Increase and densification of fat
Diffuse enlargement of muscle and tendon insertion (usually restricted to one muscle)
Enhances post contrast
Mass effect

Globe invasion and bone erosion are not common

Idiopathic inflammatory orbital syndrome (diffuse) Female, 52 years. Painful left proptosis twenty days.

Both axial MRI T1 gadolinium - fat sat.

Increased and contrast enhancement volume of the medial, lateral and superior rectus muscles, diffuse densification of retrobulbar fat involving the optic nerve. Increased volume of the eyelids

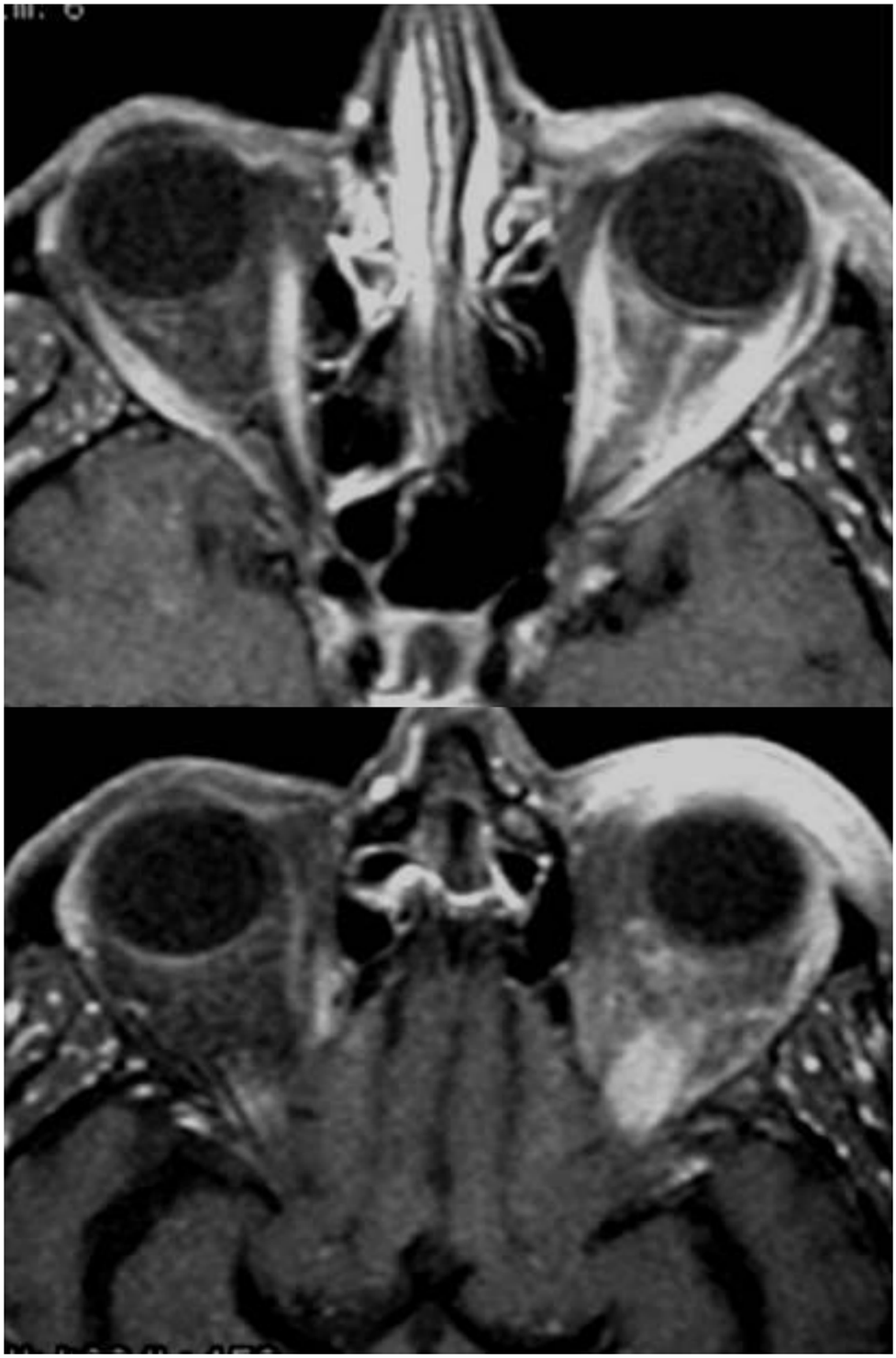

LYMPHOMA

Pathology	Clinical findings
Second most common orbital disease (only after endocrine ophthalmopathy) 10 -15 % of the orbital masses 55% of malignant orbital tumours Lymphoma non Hodgkin extranodal B cells Adults above 50 years 75% will develops systemic lymphoma	Expansive mass No pain Proptosis Mostly unilateral, but bilateral masses are more specific Alteration of eye motricity

LYMPHOMA

MRI:
Heterogeneous mass
Ill defined
Intermediate T2 sign (high cellularity)
Heterogeneous enhancement
Expansile effect, remodeling bone but rarely eroding
Like idiopathic inflammatory syndrome it can affect the optic nerve on a diffuse way

Tricky differential diagnosis with idiopathic inflammatory syndrome, both respond to corticotherapy and have similar histopathological findings

(Lymphoma) Female, 45. Painless progressive left proptosis since about a month ago. On examination there is hyperaemia of the conjunctiva and ipsilateral eyelid edema

Multicompartmental retroocular infiltration

Increased volume and heterogeneous signal hyperintensity on T2WI of both, the extrinsic muscles and the retrobulbar fat, with loss of anatomical distinction

Extrinsic muscles enhancement, with slightly increased volume and heterogeneous involvement of the retrobulbar fat

A and B. MRI Coronal T2.

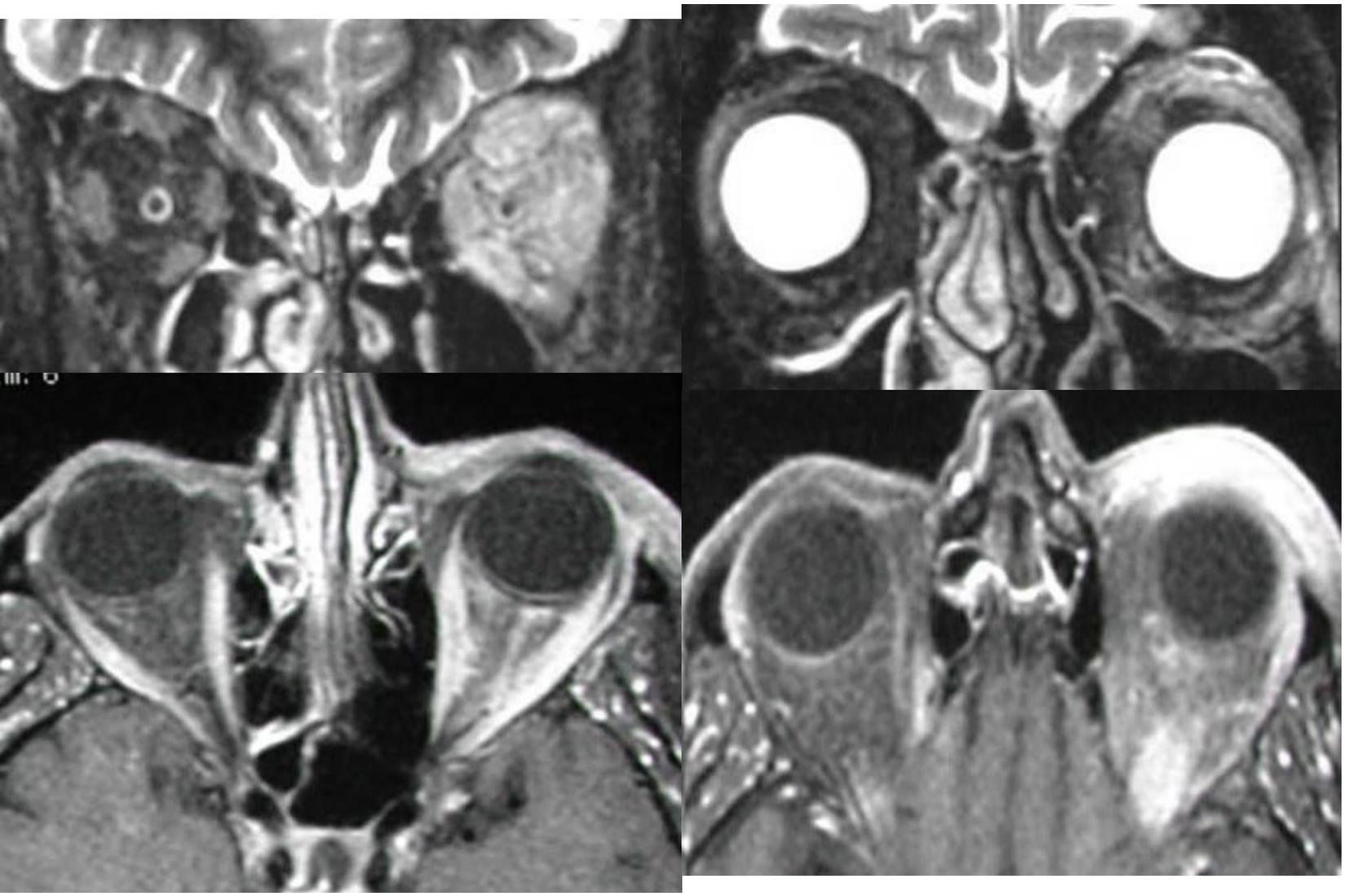

C and D. Axial T1 fat sat post- gadolinium

OTHER STUFF

Septo-optic dysplasia

Congenital disease

Atrophy of optic nerve

Associated brain malformations

Dysgenesis of the corpus callosum

Absence of the septum pellucidum

Schizencephaly (70%)

DRUSA

Punctiform hyaline material deposition in the optic disc. When calcified can be seen on CT

Ectasia of the optic nerve sheath

Not a pathology *per se* but can be found in Neurofibromatosis and intracranial hypertension for instance

Schwannomas

Tricky question! Remember that there is no Schwann cells surrounding the optic nerves

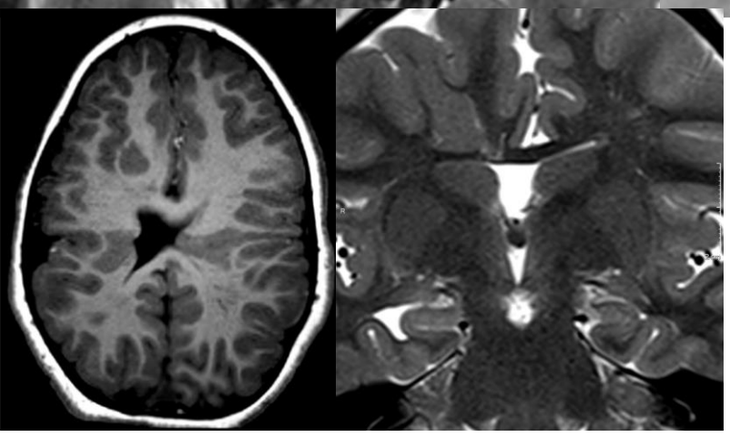

(Septo-optic dysplasia): Mild optic nerve atrophy. Other findings: schizencephaly and absence of septum pellucidum

(Ectasia of the optic nerve sheath): Increased bilateral optic nerve sheath, and rectification of the posterior wall of the globe may be related to increased intracranial pressure

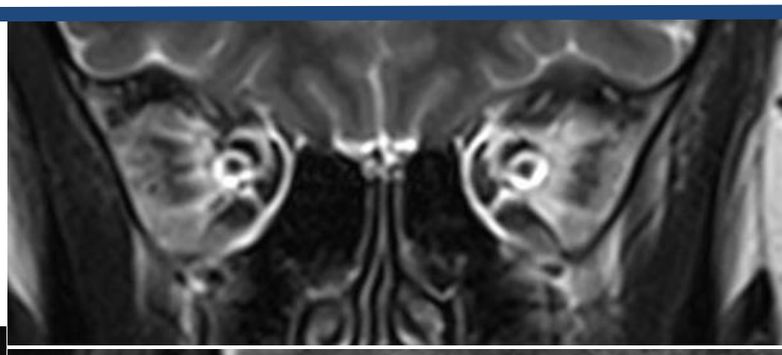

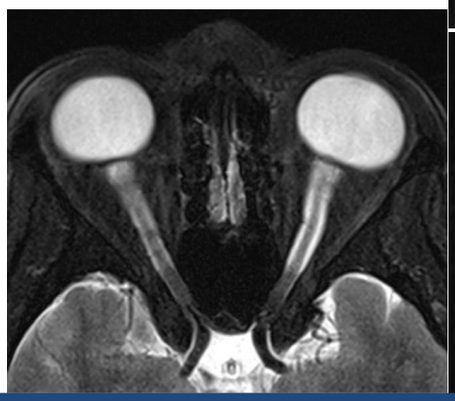

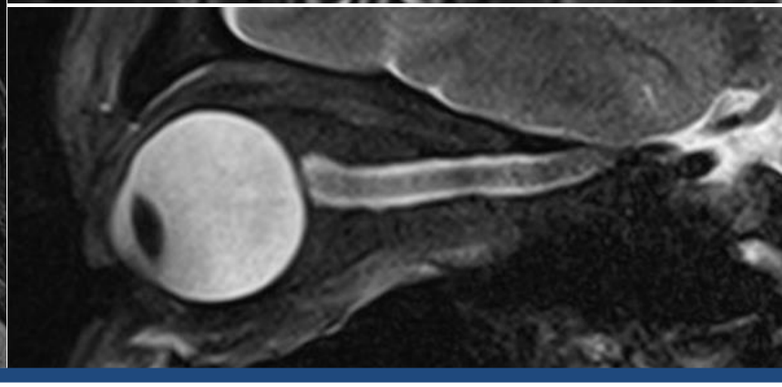

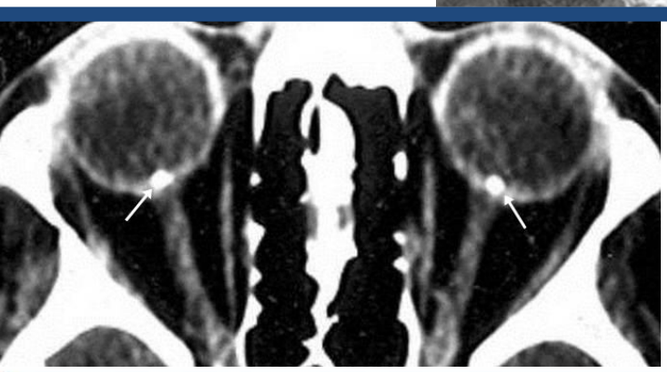

(Drusa): Calcified hyaline deposition in both eyes (arrows)

BIBLIOGRAPHY

1.Tailor TD, Gupta D, Dalley DW, et al. Orbital neoplasm in adults: clinical, radiologic, and pathologic review. Radiographics. 2013;33:1739–58.
2.Jacobs DA, Galetta, SL. Neuro-Ophthalmology for Neuroradiologists. AJNR January 2007 28: 3-8.
3. Hendrix LE, Kneeland JB, Haughton VM, Daniels DL, Szumowski J, Williams AL, et al. MR imaging of optic nerve lesions: value of gadopentetate demeglumine and fat-suppression technique. AJNR Am J Neuroradiol 1990; 11: 749–54.
4.Sheth S, Branstetter BF. 4th, Escott EJ. Appearance of normal cranial nerves on steady-state free precession MR images. RadioGraphics 2009;29(4):1045–1055.
5. Dutton, JJ. Radiology of the Orbit and Visual Pathways. Philadelphia: Saunders Elsevier, 2010.
6.Diagnostic Imaging: Head and Neck, 2nd ed. Harnsberger HR, Glastonbury CM, Michel MA, Koch BL. Philadelphia: Amirsys, 2011.
7.Imaging of the Head and Neck, 2nd ed. Mafee MF, Valvassori GE, Becker M. New York: Thieme, 2005.
8.Head and Neck Imaging, 5th ed. Som PM, Curtin HD. St. Louis: Mosby, 2011.
9.Radiologia e Diagnóstico por Imagem - Cabeça e Pescoço - Gebrim EMS, Chammas MC, Gomes RLE. São Paulo: Guanabara Koogan, 2010.
10.Harnsberger HR, 2016, 'Optic Nerve (CN2)' Amirsys Inc. Statdx Premier, viewed 25/08/2016, https://my.statdx.com/document/optic-nerve-cn2/7f9c85c2-0fc3-4ab8-a3bb-a585cc9f9717>.
11.Davidson HC, 2016, 'Optic Nerve/Sheath Complex)' Amirsys Inc. Statdx Premier, viewed 25/08/2016, https://my.statdx.com/document/optic-nerve-sheath-complex/5da2157b-83be-4ecf-947a-e6234e2c2fa2>.
12.Harnsberger HR, 2016, 'Orbit' Amirsys Inc. Statdx Premier, viewed 25/08/2016, https://my.statdx.com/document/orbit/6e2fa0fd-110e-4e2c-9fed-d948d204632f>.